



**PATIENT**

Scout Vandre

**SPECIES**

Canine

**BREED**

Greyhound

**SEX**

Female Spayed

**AGE**

9.5 years

**WEIGHT**

56lbs

**INTERPRETED BY**

Maggie Machen Lamy,  
DVM, DACVIM  
(Cardiology)

**IMAGING PERFORMED BY**

Kevin Kicker, DVM

**HOSPITAL NAME**

Wauwatosa Veterinary  
Clinic

**REFERRING VET**

Dr. Kicker

**INVOICE**

46975

**DATE**

2/24/26

**PRESENTING CLINICAL SIGNS**

History: Grade 3/6 heart murmur. Elevated BNP: 1331. Assess prior to dental. Sedated with Torb.

**RADIOGRAPHIC FINDINGS** \*NOTE: Images submitted for supplemental cardiac information only.

Normal cardiac silhouette. No obvious evidence of CHF.

**ECHOCARDIOGRAM FINDINGS**

2D, m-mode, color flow and doppler imaging is available. Mild thickening of the mitral valve leaflets with no obvious prolapse into the left atrial lumen. Trace mitral regurgitation is identified. Normal left atrial dimension. Normal LV diameter with adequate myocardial function. The tricuspid valve appears subjectively normal, with trace tricuspid regurgitation. The right heart is normal (subjective). No overt evidence of pulmonary arterial hypertension. The pulmonic and aortic valves are normal in morphology and mobility. No aortic abnormalities identified; however, the LVOT velocity is mildly elevated. Normal pulmonic outflow velocities. No aortic or pulmonic insufficiency. No pericardial or pleural effusion noted. No cardiac tumors observed.

**CARDIAC CHART**

CANINE CARDIAC PARAMETERS	MR VMAX (m/s)	TR VMAX (m/s)	LA/AO (Boon method)	LA/AO (Heart Base; Swe)	FS (%)	EF (%)	EPSS (cm)
<b>NORMAL PARAMETER</b>	4.5-5.5	<2.7	1.3	<1.6	28-40	40-100	<0.6
<b>PATIENT</b>	NA	NA	NM	1.2	33	63	0.3
CANINE CARDIAC PARAMETERS	HR (BPM)	AV VMAX (m/s)	PV MAX (m/s)	BODY WEIGHT (kg)	LA 2D short axis Base view (cm)	LVIDd Avg; 2D and m-mode short axis (cm)	LVIDs Avg; 2D and m-mode short axis (cm)
<b>NORMAL PARAMETER</b>	50-100	0.7-1.7	0.7-1.6	BELOW	BELOW	BELOW	BELOW
<b>PATIENT</b>	90	1.9	1.1	25.4	3.1	4.7	3.2
*Normal chamber parameters expressed as a mean value (SD)				3	1.27 (5.3)	2.46 (2.46)	1.36 (5.5)
<b>BODY WEIGHT DEPENDENT PARAMETERS</b>				5	1.40 (4.5)	2.74 (5.2)	1.60 (4.7)
*Note: All measurements based upon multi-modal images and methods. An average value is reported.				10	1.50 (3.8)	3.27 (3.5)	2.06 (3.1)
				15	1.83 (2.0)	3.71 (2.4)	2.43 (2.1)
				20	2.02 (1.9)	4.14 (2.2)	2.80 (2.0)
				25	2.18 (2.4)	4.48 (2.9)	3.10 (2.5)
				30	2.33 (3.3)	4.83 (3.9)	3.39 (3.4)
				35	2.48 (4.3)	5.17 (5.0)	3.69 (4.5)
				40	2.62 (5.2)	5.48 (6.1)	3.96 (5.4)
				50	2.88 (7.1)	6.07 (8.3)	4.46 (7.4)

**INTERPRETATION OF THE FINDINGS & FURTHER RECOMMENDATIONS**

Overtly normal cardiac dimensions and function. The only cause of a murmur identified is increased flow velocity through the LVOT/aortic root. No obvious subaortic narrowing or valvular abnormalities are visualized, and in the absence of structural issues this is considered a benign flow murmur. If the murmur persists or progresses, it is reasonable to monitor periodically via recheck echocardiography in the future. Additionally screening for fluid status abnormalities



## PATIENT

Scout Vandre

## SPECIES

Canine

## BREED

Greyhound

## SEX

Female Spayed

## AGE

9.5 years

## WEIGHT

56lbs

## INTERPRETED BY

Maggie Machen Lamy,  
DVM, DACVIM  
(Cardiology)

## IMAGING PERFORMED BY

Kevin Kicker, DVM

## HOSPITAL NAME

Wauwatosa Veterinary  
Clinic

## REFERRING VET

Dr. Kicker

## INVOICE

46975

## DATE

2/24/26

(dehydration, anemia, etc.) is recommended through routine lab work as volume changes can make this finding more prevalent. Trace MR and TR may reflect early valve disease; however, a physiologic origin is also possible. Monitoring for progression is advised. No significant valvular insufficiencies were noted and no structural issues identified.

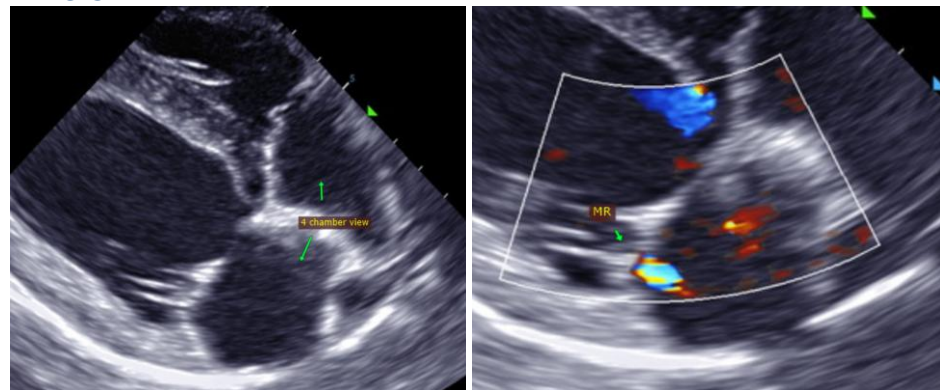
No cardiac medications are indicated. Prognosis is open.

No cardiac contraindication for general anesthesia.

Monitor for any development of cough, labored breathing or exercise intolerance.

Recommend recheck echocardiogram in 1 year to screen for development of concurrent cardiac disease that the preexisting murmur may mask.

## IMAGES



**The information and recommendations provided are based on the images presented by the referring veterinarian. No evaluation can be communicated regarding pathology that was not visible in the image/video clips provided.**

Thank you for this referral. This report was generated using transcription software, and minor dictation errors may be present. If the clinical or image interpretation does not parallel your findings or if I can be of any further assistance, please contact me.

**Maggie Machen Lamy, DVM**  
**Diplomate of the American College of Veterinary Internal Medicine (Cardiology)**  
info@sonopath.com